

Right Sided Aortic Arch Associated with Limb Length Discrepancy: A Rare Vaso Occlusive Manifestation

Saugata Acharyya^{1*}
Sanchari Chakravarty²

¹Consultant Pediatrician, Calcutta Medical Research Institute, 63 Raja Basanta Roy Road, Kolkata, India

²Post Graduate Resident, Calcutta Medical Research Institute, Kolkata, India

Abstract

Background: Right aortic arch is rare. It may be associated with critical subclavian stenosis.

Case characteristics: A three month old baby presented with visible shortening of left arm.

Observation: CT angiogram revealed right aortic arch with stenosis of left subclavian artery.

Outcome: Gradual correction of limb discrepancy after successful Stenting.

Message: Vaso-occlusive features may be a rare presentation of aortic arch anomalies.

Keywords

Right aortic arch; Subclavian stenosis

Introduction

Right sided aortic arch is extremely rare. It may be associated with other congenital anomalies. We describe an unusual case of a three month old baby. The parents were concerned about visible shortening of his left arm. The baby was born following IVF pregnancy. He was ventilated following birth for features of hyaline membrane disease. An echocardiogram performed during neonatal period revealed a right sided aortic arch. Follow-up CT angiogram revealed right aortic arch associated with severe proximal stenosis of the left subclavian artery and an ectopic left kidney. Successful Stenting of left subclavian stenosis gradually reduced the limb length discrepancy.

Case Report

A female baby was born by LSCS following an IVF pregnancy at 35 weeks gestation. The birth weight was 2.41 kg with an Apgar score of 9 at 1 minute and 9 at 5 minutes. There was a history of previous pregnancy loss with baby having multiple congenital anomalies. However the antenatal period during this pregnancy was uneventful. The baby developed tachypnoea and grunting soon after birth. The chest x-ray revealed features of hyaline membrane disease and the arterial blood gas showed significant respiratory acidosis. Therefore the baby was put on conventional mechanical ventilation on day 1. Natural surfactant was administered. The baby responded very well and was extubated into head box oxygen after 48 hours. There was one episode of focal seizure which was attributed to documented hypocalcaemia and treated with intravenous calcium administration. Subsequently feeds were started and baby was discharged on day 11.

During this period an echocardiography was performed. This revealed a right sided aortic arch in a structurally normal heart. A follow up CT angiogram was advised at a later stage for a detailed assessment of the arch anatomy. An ultrasound of the abdomen could not locate the left kidney and a follow up DMSA scan was requested.

At the age of 3 months the baby was brought for a routine follow up. Her weight was 3.1 kg and was essentially asymptomatic. However the parents were extremely concerned about a visibly smaller and thinner left arm (Figure 1). On measurement, the length (from the tip of the acromion process to the tip of the middle finger) of the right upper extremity was 22.2 cm in comparison to the left side of 21.4 cm with a difference of 8 mm. Accordingly the mid arm circumference of the right arm was 12.5 cm and that of left arm was 11.5 cm with a difference of 10 mm. Therefore there was an obvious shortening of the left arm. As planned initially, a CT angiogram was performed. This revealed a right sided aortic arch along with significant stenosis of the proximal part of the left subclavian artery. The CT angiogram also showed the presence of an ectopic left kidney at the pelvis supplied by two aberrant left renal arteries. A detailed left subclavian artery angiogram confirmed the presence of the stenosis at the origin and the absence of significant collateral vessels supplying the left arm. Hence it was decided that stent will be inserted at the site of the stenosis. This was performed successfully and the child was discharged home. 3 months following the stent insertion the child was seen again. At that time the measurement revealed the length of the right arm was 23.5 cm and that of left arm was 22.9 cm (difference reduced from 8 mm

Article Information

DOI: 10.31021/ijcmc.20181102

Article Type: Case Report

Journal Type: Open Access

Volume: 1 **Issue:** 1

Manuscript ID: IJCMC-1-102

Publisher: Boffin Access Limited

Received Date: January 27, 2018

Accepted Date: February 20, 2018

Published Date: March 05, 2018

*Corresponding author:

Saugata Acharyya

Consultant Pediatrician

Calcutta Medical Research Institute

63 Raja Basanta Roy Road

Kolkata 700029

India

Telephone number: +919830068567

E-mail: Acharyyasaugata@Yahoo.Com

Citation: Acharyya S, Chakravarty S. Right Sided Aortic Arch Associated with Limb Length Discrepancy: A Rare Vaso Occlusive Manifestation. *Int J Clin Med Cases*. 2018 Mar;1(1):102

Copyright: © 2018 Acharyya S, et al. This is an open-access article distributed under the terms of the Creative Commons Attribution 4.0 international License, which permits unrestricted use, distribution, and reproduction in any medium, provided the original author and source are credited.

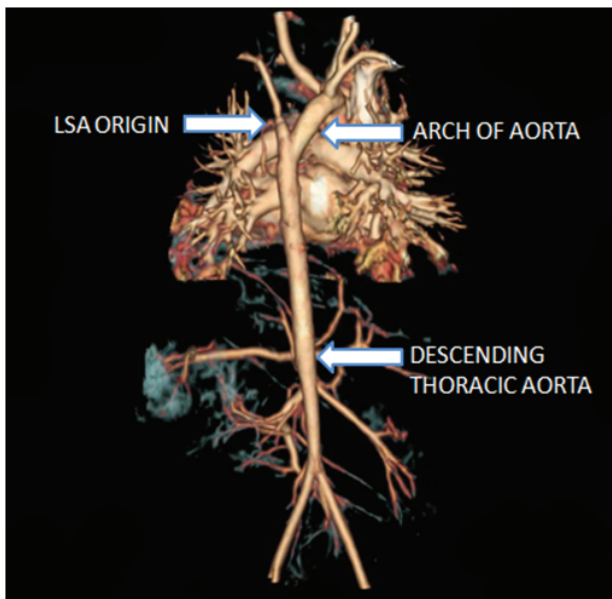


Figure 1: CT angiogram showing severe stenosis at LSA origin

to 6 mm following stent insertion). Also the mid arm circumference of the right arm was 13.2 cm and that of the left arm was 12.7 cm (difference reduced from 10 mm to 5 mm).

Discussion

Right sided aortic arch is a type of aortic arch variant occurring in 0.1% (0.05-0.2%) population. It may be of 3 types. Type I is the right aortic arch with mirror image branching like that of a left aortic arch. In some studies this was reported as the most common variant which is usually associated with cyanotic congenital heart disease [1]. Type II is a right aortic arch associated with an aberrant subclavian artery that may arise from a diverticulum and may be associated with a vascular ring giving rise to pressure effect on the trachea or esophagus [2]. Some studies reported this being the most common variant [3]. This type however is rarely associated with any major congenital cardiac anomalies. Type III is by far the least common type of the right sided aortic arch. This variety is again rarely associated with congenital heart disease. However it may be associated with manifestations of steno occlusive disease of the left subclavian artery. The later may in extreme cases give rise to the features of subclavian steal syndrome.

Right sided aortic arch is often associated with vascular ring. About 20% of such cases may show features of vello- cardio-facial (CATCH

22) syndromes. They are associated with hypocalcaemia, typical facial features and T cell immune among other things. Chromosomal analysis reveals 22q11 deletion. Right aortic arch may form a part of the random association known by CHARGE (consisting of coloboma, heart defect, atresia choanae, retardation, genital and ear anomalies). Finally, right aortic arch may form a part of the VACTERL association. This is a non random co occurrence of birth defects that include vertebral, anal, cardiac, trachea esophageal, renal/ radial and limb abnormalities. The exact etiology of this association is not defined. However it is most likely caused by multiple factors [4]. The presence of at least 3 (some suggest 2) features are required to diagnose this rare association (incidence of 1.6 per 10000 live births).

In the case we report a three month old baby who had an obvious left upper limb shortening. A detailed CT angiogram showed a right sided aortic arch with significant stenosis at the origin of left subclavian artery. The limb length discrepancy was most likely caused by this stenosis. This was gradually corrected following successful insertion of stent at that site. Though there was history of hypocalcaemia but chromosomal analysis did not reveal any evidence of 22q11 deletion. The child did not have any other abnormalities apart from a pelvic left kidney.

In our opinion this is an extremely rare presentation of Vaso-occlusive features (caused by critical stenosis of left subclavian artery) associated with right aortic arch and ectopic left kidney. We strongly suggest a detailed follow-up CT angiogram in every diagnosed case of right sided aortic arch. The later may be associated with other congenital vascular anomalies even with a structurally normal heart. In case we do not do this, there is all likelihood that we miss some interesting cases like the ones we reported.

References

1. Chai OH, Han EH, Kim HT, Song DH. Right sided aortic arch with retro esophageal left subclavian artery as the fourth branch. *Anat Cell Biol.* 2013 Jun;46(2):167-170.
2. Hara M1, Kitase M, Satake M, Miyagawa H, Ogino H, et al. A case of right sided aortic arch with isolation of left subclavian artery: CT findings. *Radiat Med.* 2001 Jan-feb;19(1):33-36.
3. Turkvatan A, Buyukbayraktar FG, Olcer T, Cumhuri T. Congenital anomalies of the aortic arch: Evaluation with the use of multidetector computed tomography. *Kor J Radiol.* 2009 Mar-Apr;10(2):176-84.
4. Hersh JH1, Angle B, Fox TL, Barth RF, Bendon RW, et al. Developmental field defects: coming together of associations and sequences during blastogenesis. *Am J Med Genet.* 2002 Jul;110(4):320-323.