

Journal of Cancer Research and Oncobiology

Radiographic Depiction of Multiple Odontomes

Suraj Agarwal¹¹Department of Oral Medicine & Radiology, ITS Dental College, Hospital & Research Centre, Greater Noida, India.

Abstract

A 10-year-old male patient visited the department of oral medicine and radiology with a chief complaint of pain and swelling on right side of the face. A patient gave the history of swelling on right side of lower 1/3rd of face since 7-8 years with dull, intermittent pain which aggravates on taking food for 1 month. The patient had undergone radiographic investigations and biopsy on the right side of face 15 days back. On extra oral examination, swelling on right side of lower 1/3rd of face extending anteroposteriorly from a straight line drawn from inner canthus of the eye, posteriorly 1 cm beyond outer canthus of the eye. Supero-inferiorly from a straight line drawn from commissure of the lip to 1 cm beyond the inferior border of mandible. Swelling is approximately 4x4 cm in size. The overlying skin has increase pigmentation with sinus opening, tender on palpation, bony hard. Right sub mandibular lymph node palpable, mobile and tender. On intra-oral examination, obliteration of vestibule from 44 to 47. The provisional diagnosis of chronic suppurative osteomyelitis. OPG reveals dense, homogeneous radio-opaque mass on right side of the body with surrounding radiolucent halo extending from 44 to 47. Supero-inferiorly from the superior border of the mandible to the inferior border of the mandible to the inferior border of the mandible with multiple tooth-like structures at the inferior border of the mandible. There is thinning of the inferior cortex of mandible with a divergence of 43, 44, and 47. CECT reveals a well define lobulated mass with few hypodense areas, measures approximately 37x36x29 mm. the mass is causing significant bi-cortical expansion of mandible. Radiographic diagnosis- odontomas. Excisional biopsy was performed and a histopathologic diagnosis was COMPOUND COMPOSITE ODONTOME.

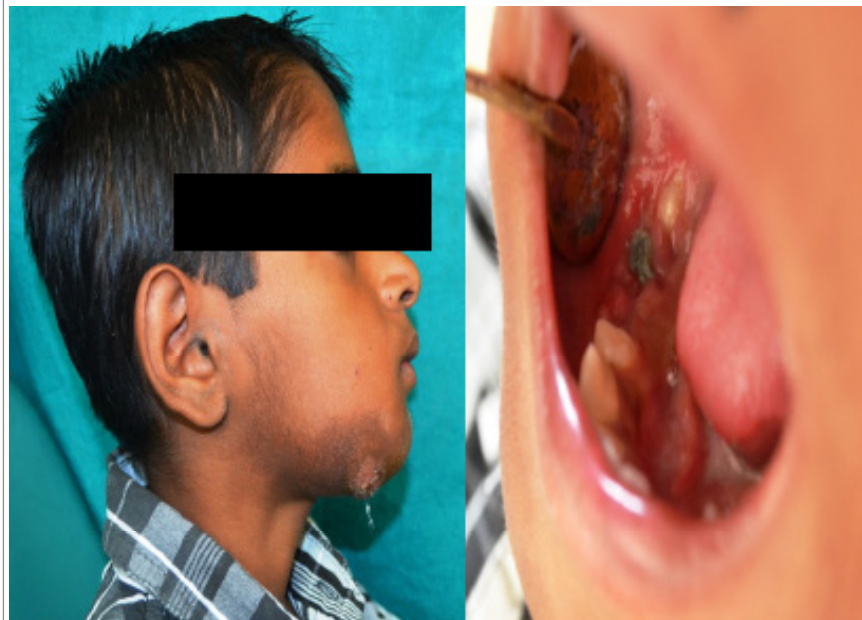

Figure1: swelling on right side of lower 1/3rd of face

Article Information

DOI:	10.31021/jcro.20181102
Article Type:	Clinical Image
Journal Type:	Open Access
Volume:	1 Issue: 1
Manuscript ID:	JCRO-1-102
Publisher:	Boffin Access Limited
Received Date:	20 November, 2017
Accepted Date:	02 January, 2018
Published Date:	12 January, 2018

*Corresponding author:

Suraj Agarwal

Department of Oral Medicine & Radiology
ITS Dental College
Hospital & Research Centre, Greater Noida, India
Tel: + 9927488170
Email: surajagarwal@yahoo.co.in.

Citation: Suraj A. Radiographic Depiction of Multiple Odontomes. J Cancer Res Oncobiol. 2018 Jan; 1(1):102.

Copyright: © 2018 Agarwal S. This is an open-access article distributed under the terms of the Creative Commons Attribution 4.0 international License, which permits unrestricted use, distribution, and reproduction in any medium, provided the original author and source are credited.

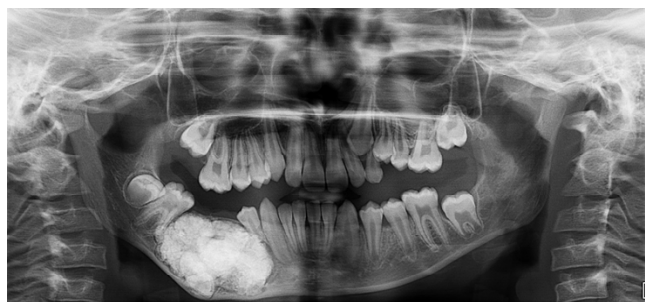

Figure 2: Extra Oral Radiograph

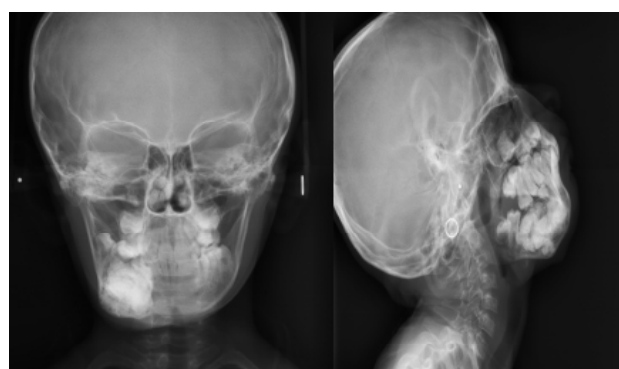


Figure 3: CECT Imaging

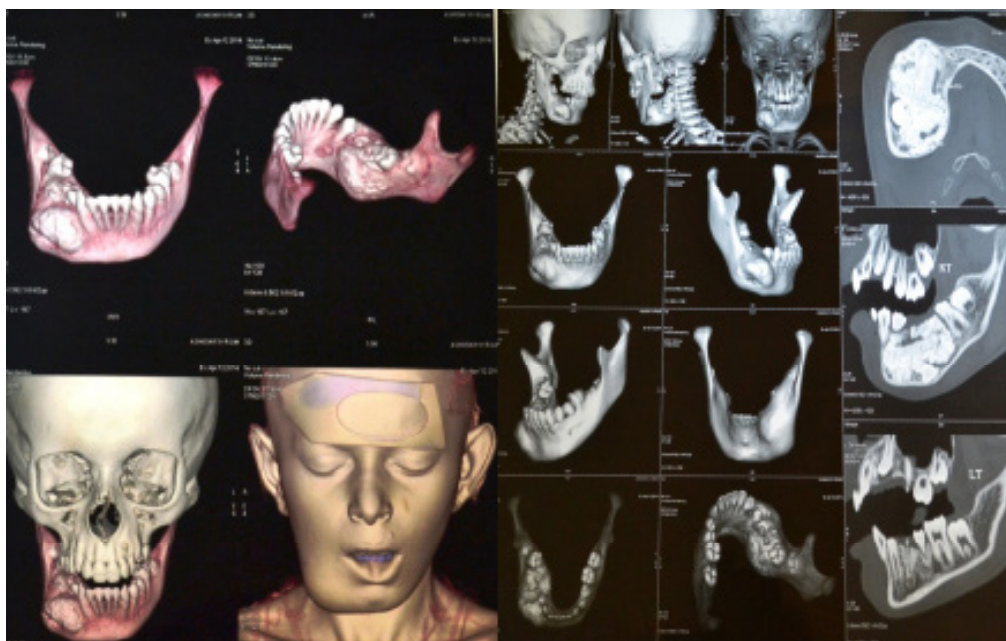


Figure 4: CECT Imaging

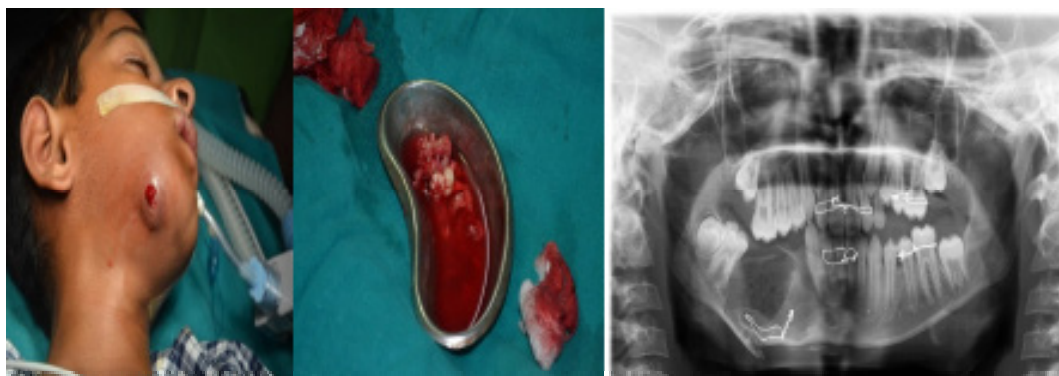

Figure 5: Intra Operative Postoperative